



Chromatophoromas and Related Hyperplastic Lesions in Pacific Rockfish (*Sebastes* spp.)

M. S. Okihira,^a J. A. Whipple,^b J. M. Groff^a
& D. E. Hinton^a

^a Department of Medicine, School of Veterinary Medicine, University of California—Davis, Davis, California 95616, and

^b National Marine Fisheries Service, Southwest Fisheries Science Center, Tiburon, California 94920, USA

ABSTRACT

*Pacific rockfish were sampled from Cordell Bank, off central California, from 1985 to 1990. Hyperplastic and neoplastic lesions, involving dermal chromatophores, were observed in five species: yellowtail rockfish (*Sebastes flavidus*), bocaccio (*S. paucispinis*), olive rockfish (*S. serranoides*), widow rockfish (*S. entomelas*), and chilipepper rockfish (*S. goodei*). Yearly prevalences were highest, but static, in *S. paucispinis*, while prevalences in *S. flavidus* have risen steadily. The majority of lesions were black, but white, red, orange, yellow, and mixed color variants were also seen. Lesions were found in skin, fins, lips, gingiva, tongue, urogenital papilla, and in the conjunctiva and cornea of the eye. Flat lesions were consistent with either melanophore (black), erythrophore (red), or xanthophore (yellow) hyperplasia. Neoplastic lesions included melanophoromas, amelanotic melanophoromas, xanthophoromas, erythrophoromas, and mixed chromatophoromas. Electron microscopy did not reveal the presence of viruses and the etiology of the lesions has not been determined.*

Pacific rockfish are ovoviviparous marine fish that are extensively fished. One of the most popular fishing areas is Cordell Bank, the northernmost sea mount in the California continental shelf. The bank is the primary site of ongoing rockfish recruitment studies by the National Marine Fisheries Service. Over the course of numerous sampling trips, pigmented lesions consistent with chromatophore hyperplasia and neoplasia (chromatophoromas) were observed in five species of rockfish: yellowtail rockfish

(*Sebastes flavidus*), bocaccio (*S. paucispinis*), olive rockfish (*S. serranoides*), widow rockfish (*S. entomelas*), and chilipepper rockfish (*S. goodei*).

Chromatophoromas are cutaneous pigment cell tumors that arise from dermal chromatophores normally present in skin. Chromatophoromas are common tumors and large epizootics have occurred in marine and freshwater environments. Species of marine fish involved include (1) croakers (*Nibea mitsukurii*) off the Pacific coast of Japan,¹ (2) deepwater redfish (*Sebastes mentella*) in the North Atlantic,² and (3) butterflyfish (*Chaetodon multicinctus* and *C. miliaris*) from the Hawaiian Islands.³

The purpose of this study was to characterize the gross, histologic, and electron microscopic features associated with pigmented lesions in rockfish sampled from Cordell Bank from 1985 to 1990. Prevalence and scoring (based on severity of hyperplastic and neoplastic melanophore lesions) data were determined for all species except *S. serranoides*. Selected lesions were processed for light and electron microscopy.

Yearly prevalences were consistently higher in *S. paucispinis*, with the highest prevalence, 38.6%, occurring in 1987 (Table 1). Prevalence in *S. flavidus* was initially low, but increased more than three-fold from 1985 to 1990. Melanophoromas were primarily found in *S. flavidus* and prevalence varied from 0% (1985) to 8.6% (1990). Xanthophore (yellow and orange) and erythrophore (red) lesions were only observed in *S. flavidus*. Prevalence of melanophore lesions was consistently higher in male versus female *S. flavidus* and *S. goodei*, but was nearly equal in *S. paucispinis*. The prevalence of all lesion types increased with age.

The average melanophore lesion score was significantly higher in *S. flavidus* (19.8%) compared with the other three species (10.5–10.9%).

TABLE 1
Prevalence of Hyperplastic and Neoplastic Pigmented Skin Lesions in *S. flavidus*, *S. paucispinis*, *S. entomelas*, and *S. goodei* Collected from Cordell Bank from 1985 to 1990

Year	% Prevalence (number of fish with lesions/number of fish examined)			
	<i>S. flavidus</i>	<i>S. paucispinis</i>	<i>S. entomelas</i>	<i>S. goodei</i>
1985	7.5 (7/94)	35.1 (13/37)	6.3 (1/16)	8.2 (4/49)
1986	11.3 (15/133)	29.0 (11/38)	5.3 (1/19)	16.7 (3/18)
1987	9.8 (15/153)	38.6 (17/44)	0.0 (0/8)	ND
1988	11.0 (12/109)	37.8 (14/37)	0.0 (0/2)	ND
1989	16.8 (17/101)	ND	ND	ND
1990	25.5 (56/220)	ND	ND	ND

ND = not determined.

Average scores for *S. flavidus* increased markedly with age, and males scored higher than females. There were minimal differences in lesion scores between male and female *S. paucispinis* or *S. goodei*, and no appreciable change in lesion scores as these fish aged. Melanophore lesions in *S. flavidus* had a dorsal and anterior distribution while the opposite was true for *S. goodei*. Melanophore lesions in *S. paucispinis* and *S. entomelas* were more severe ventrally.

Pigmented lesions in *S. flavidus* were found in the skin, fins, lips, gingiva, tongue, urogenital papilla, and in the conjunctiva and cornea of the eye (Fig. 1). The majority were black, but white, red, orange, yellow, and mixed color variants were also seen. The smallest lesions were round to irregular, flat foci that varied from 0.1 to 2 cm in diameter. In severely affected fish, foci coalesced to form large areas of melanosis. Raised masses, varying from 0.2 to 2 cm in diameter, were occasionally found. Masses were usually solid black, but other color variants were also occasionally seen. Lesions in *S. serranoides* were very similar to those in *S. flavidus* except that no yellow, orange, or red lesions were seen. Lesions in *S. paucispinis* were primarily found over the flanks, and were limited to flat foci of benign melanosis. Lesions in *S. entomelas* were similar to those in *S. serranoides*, and those in *S. goodei* similar to lesions in *S. paucispinis*.

Histologically, the smallest foci of melanosis were characterized by




Fig. 1. *S. flavidus* with severe melanophore hyperplasia involving the dorsal aspect of the flanks, pectoral fin, lips, and conjunctiva of the eye. Bar = 2.5 cm.

hyperplasia of melanophores in the superficial dermis. Hyperplasia varied from mild to severe. Areas of severe hyperplasia often graded into small foci of dysplasia (mild to moderate disorganization and pleomorphism) and early neoplasia (accentuated disorganization, variability in pigmentation, and pleomorphism). All neoplasms with predominantly melanin bearing cells were classified as melanophoromas. Melanophoromas were composed of pleomorphic populations of stellate to spindle cells arranged into tightly packed, interweaving fascicles and whorling bundles (Fig. 2). The degree of pigmentation was highly variable and predominantly white tumors were classified as amelanotic melanophoromas. Xanthophoromas and erythrophoromas were not distinguishable from either each other or from amelanotic melanophoromas in routine HE sections and classification was based on the gross coloration prior to fixation. Yellow and orange tumors were classified as xanthophoromas and red tumors identified as erythrophoromas. Liver masses from one *S. flavidus* and gill masses from one *S. serranoides* were consistent with metastases.

Tissue for electron microscopy was only collected from *S. flavidus*. Melanophores were characterized by the presence of melanosomes, erythrophores by lipid, and xanthophores by lipid and pterinosomes. A few tumors contained widely scattered iridophores with reflecting platelets.

The gross, histologic, and electron microscopic features of pigmented

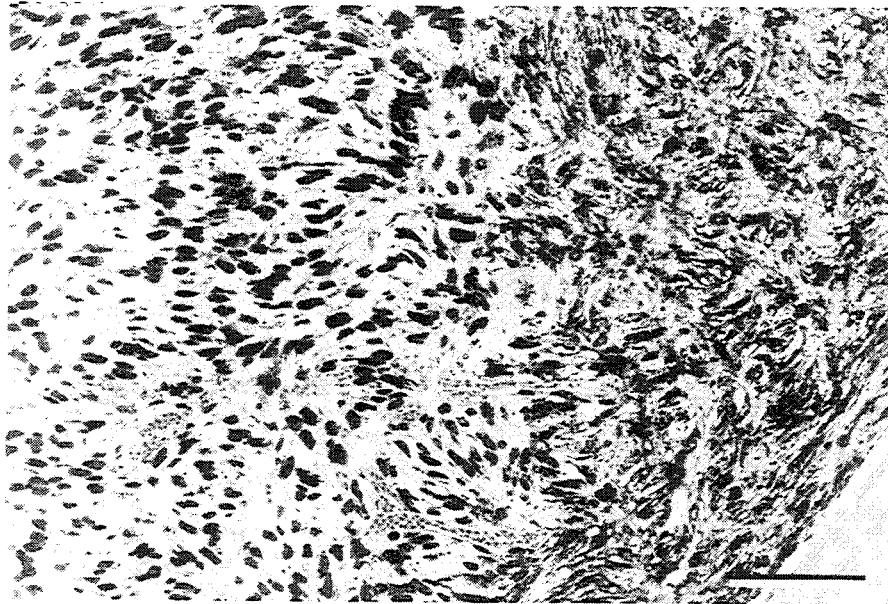


Fig. 2. Melanophoroma composed of a pleomorphic population of spindle cells heavily laden with melanin. Bar = 50 μ m.

lesions in rockfish were all consistent with the diagnosis of chromatophore hyperplasia and neoplasia. Hyperplastic lesions are likely precursor lesions of chromatophoromas and progression appears to occur stepwise from mild melanophore hyperplasia to severe hyperplasia, dysplasia, and eventual neoplasia (melanophoroma). Xanthophore and erythrophore hyperplasia probably precede formation of xanthophoromas and erythrophoromas. The etiology is unknown, but interest is currently focused on waters surrounding the Farallon Islands (south of Cordell Bank) which were used as a radioactive and toxic waste disposal site from 1946 to 1970. Approximately 47 500 barrels of low-level radioactive waste and 47 800 barrels of unspecified toxic waste were dumped at three sites.⁴ Limited sampling has already revealed high levels of chlorinated hydrocarbons (DDTs and PCBs) in sablefish (*Anoplopoma fimbria*) and Dover sole (*Microstomus pacificus*),⁵ and trace levels of plutonium-239 in *S. flavidus*. Efforts are underway to expand the study area to include the Farallons in order to establish a more definitive link between the cutaneous lesions in rockfish and possible exposure to carcinogenic compounds in the environment.

ACKNOWLEDGEMENTS

The authors thank all the staff of the Tiburon laboratory of the National Marine Fisheries Service for technical assistance and for help in the collection of specimens. This study was supported in part by Public Health Service Grant CA45131 from the National Cancer Institute.

REFERENCES

1. Kimura, I., Taniguchi, N., Kumai, H., Tomita, I., Kinae, N., Yoshizaki, K., Ito, M. & Ishikawa, T. *Natl Cancer Inst. Monogr.*, **65**, 139-54 (1984).
 2. Bogovski, S. P. & Bakai, Y. I. *J. Fish Dis.*, **12**, 1-13 (1989).
 3. Okihiro, M. S. *Vet. Pathol.*, **25**, 422-31 (1988).
 4. Karl, H. A. & Drake, D. E. *Geo. Soc. Am. Abstr.*, **12**, 40 (1991).
 5. Melzian, B. D., Zoffman, C. & Spies, R. B., *Mar. Poll. Bull.*, **18**, 388-93 (1986).
-